


# INADEQUATE SURGERY IN ENDOMETRIAL CANCER

Narges,Zamani MD



3

# History


- ▶ A 60-year-old woman , who was virgin and premenopausal went to the hospital 4 months ago . Her chief complaint was menometrorrhagia.
  - ▶ PMH : HTN
  - ▶ DH : enalapril
  - ▶ FH : Breast cancer in her sister
  - ▶ PH/EX : not done
- 

# sonography

- ▶ **Uterus** : is larger than normal due to adenomyosis ,EL is 3 MM.
- ▶ **Ovaries** : atrophic

# surgery

- ▶ STAH + BSO



positive for malignancy



Pre -OP evaluation?

# pathology

- ▶ **Endometrioid Adenocarcinoma**
- ▶ **site: endometrium**
- ▶ **grading : G2**
- ▶ **LVI : negative**
- ▶ **myometrial invasion : deep (15/16 mm)**
- ▶ **Uterine serosa involvement: very closed(1 mm)**
- ▶ **Endocervical margin :involved**
- ▶ **Parametrial margin :very closed (2mm)**
- ▶ **Ovaries & fallopian tubes :unremarkable**

# further treatment



Further treatment options for endometrial carcinoma incidentally diagnosed in the removed uterus ???

# Further treatment

- ▶ chest & abdominal & pelvic CT :

Supracervical  
hystrectomy +  
NO DISTANT  
METASTASIS

- ▶ SURGERY :

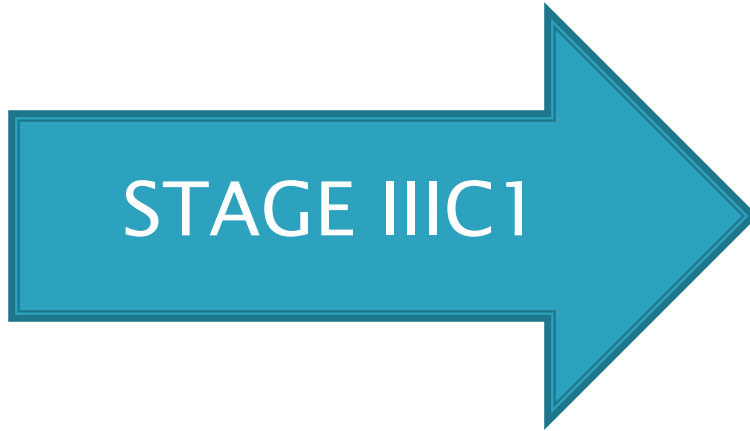Resection of cervix +  
lymphadenectomy +  
appendectomy + omentectomy



# pathology

- ▶ **Cervix** : villoglandular adenocarcinoma involving superficial epithelium , stroma is not involved
- ▶ **pelvic lymphadenectomy** : involved (2 / 7)
- ▶ **Appendix** : free of tumor
- ▶ **Omentum** : free of tumor

# management



???????

# management

- ▶ Chemotherapy T+C : 6 courses
- ▶ Radiotherapy